

PEDIATRICS®

OFFICIAL JOURNAL OF THE AMERICAN ACADEMY OF PEDIATRICS

Initiation and Use of Propranolol for Infantile Hemangioma: Report of a Consensus Conference

Beth A. Drolet, Peter C. Frommelt, Sarah L. Chamlin, Anita Haggstrom, Nancy M. Bauman, Yvonne E. Chiu, Robert H. Chun, Maria C. Garzon, Kristen E. Holland, Leonardo Liberman, Susan MacLellan-Tobert, Anthony J. Mancini, Denise Metry, Katherine B. Puttgen, Marcia Seefeldt, Robert Sidbury, Kendra M. Ward, Francine Blei, Eulalia Baselga, Laura Cassidy, David H. Darrow, Shawna Joachim, Eun-Kyung M. Kwon, Kari Martin, Jonathan Perkins, Dawn H. Siegel, Robert J. Boucek and Ilona J. Frieden

Pediatrics 2013;131;128; originally published online December 24, 2012;

DOI: 10.1542/peds.2012-1691

The online version of this article, along with updated information and services, is located on the World Wide Web at:

<http://pediatrics.aappublications.org/content/131/1/128.full.html>

PEDIATRICS is the official journal of the American Academy of Pediatrics. A monthly publication, it has been published continuously since 1948. PEDIATRICS is owned, published, and trademarked by the American Academy of Pediatrics, 141 Northwest Point Boulevard, Elk Grove Village, Illinois, 60007. Copyright © 2013 by the American Academy of Pediatrics. All rights reserved. Print ISSN: 0031-4005. Online ISSN: 1098-4275.

American Academy of Pediatrics

DEDICATED TO THE HEALTH OF ALL CHILDREN™



Initiation and Use of Propranolol for Infantile Hemangioma: Report of a Consensus Conference

abstract



Infantile hemangiomas (IHs) are common neoplasms composed of proliferating endothelial-like cells. Despite the relative frequency of IH and the potential severity of complications, there are currently no uniform guidelines for treatment. Although propranolol has rapidly been adopted, there is significant uncertainty and divergence of opinion regarding safety monitoring, dose escalation, and its use in PHACE syndrome (PHACE = posterior fossa, hemangioma, arterial lesions, cardiac abnormalities, eye abnormalities; a cutaneous neurovascular syndrome characterized by large, segmental hemangiomas of the head and neck along with congenital anomalies of the brain, heart, eyes and/or chest wall). A consensus conference was held on December 9, 2011. The multidisciplinary team reviewed existing data on the pharmacologic properties of propranolol and all published reports pertaining to the use of propranolol in pediatric patients. Workgroups were assigned specific topics to propose protocols on the following subjects: contraindications, special populations, pretreatment evaluation, dose escalation, and monitoring. Consensus protocols were recorded during the meeting and refined after the meeting. When appropriate, protocol clarifications and revision were made and agreed upon by the group via teleconference. Because of the absence of high-quality clinical research data, evidence-based recommendations are not possible at present. However, the team agreed on a number of recommendations that arose from a review of existing evidence, including when to treat complicated IH; contraindications and pretreatment evaluation protocols; propranolol use in PHACE syndrome; formulation, target dose, and frequency of propranolol; initiation of propranolol in infants; cardiovascular monitoring; ongoing monitoring; and prevention of hypoglycemia. Where there was considerable controversy, the more conservative approach was selected. We acknowledge that the recommendations are conservative in nature and anticipate that they will be revised as more data are made available. *Pediatrics* 2013;131:128–140

AUTHORS: Beth A. Drolet, MD,^a Peter C. Frommelt, MD,^b Sarah L. Chamlin, MD,^c Anita Haggstrom, MD,^d Nancy M. Bauman, MD FACS FAAP,^e Yvonne E. Chiu, MD,^f Robert H. Chun, MD,^g Maria C. Garzon, MD,^h Kristen E. Holland, MD,ⁱ Leonardo Liberman, MD,^j Susan MacLellan-Tobert, MD,^j Anthony J. Mancini, MD,^g Denise Metry, MD,^k Katherine B. Puttgen, MD,^l Marcia Seefeldt, RN,^m Robert Sidbury, MD,ⁿ Kendra M. Ward, MD MS,^o Francine Blei, MD,^p Eulalia Baselga, MD,^q Laura Cassidy, PhD,^r David H. Darrow, MD,^s Shawna Joachim,^t Eun-Kyung M. Kwon, BA,^f Kari Martin, MD,^f Jonathan Perkins, DO,^b Dawn H. Siegel, MD,^a Robert J. Boucek, MD,ⁿ and Ilona J. Frieden, MD[†]

^aDepartments of Pediatrics, and Dermatology, ^bPediatric Cardiology, ^cDermatology, ^dOtolaryngology, and ^eBiostatistics, Medical College of Wisconsin, Milwaukee, Wisconsin; ^fDepartments of Pediatrics and Dermatology, Northwestern University, Chicago, Illinois; ^gDepartments of Dermatology and Pediatrics, Indiana University, Indianapolis, Indiana; ^hDepartment of Otolaryngology, Children's National Medical Center, Washington, District of Columbia; ⁱDepartments of Dermatology, and Pediatrics, and ^jPediatrics, Columbia University, New York, New York; ^kDepartment of Cardiology, Gunderson Lutheran Hospital, La Crosse, Wisconsin; ^lDepartment of Dermatology, Baylor College of Medicine, Houston, Texas; ^mDepartment of Dermatology, Johns Hopkins Hospital, Baltimore, Maryland; ⁿDepartment of Dermatology, Children's Hospital of Wisconsin, Milwaukee, Wisconsin; ^oDepartments of Pediatrics, and Cardiology, Seattle Children's Hospital, Seattle, Washington; ^pDepartment of Pediatrics, Northwestern University, Chicago, Illinois; ^qDepartments of Hematology & Oncology, Vascular Birthmark Institute of New York, New York, New York; ^rDepartment of Dermatology, Hospital de la Santa Creu i Sant Pau, Barcelona, Spain; ^sDepartments of Otolaryngology and Pediatrics, Eastern Virginia Medical School, Norfolk, Virginia; and ^tDepartments of Dermatology & Pediatrics, University of California San Francisco, San Francisco, California

KEY WORDS

infantile hemangioma, propranolol, PHACE syndrome, hypertension, bradycardia, hypoglycemia

ABBREVIATIONS

BP—blood pressure
ECG—electrocardiogram, FDA, US Food and Drug Administration
HR—heart rate
IH—infantile hemangioma
PHACE—posterior fossa, hemangioma, arterial lesions, cardiac abnormalities, eye abnormalities

(Continued on last page)

Infantile hemangiomas (IHs) are common benign tumors composed of proliferating endothelial-like cells. The duration and rate of growth are variable; some infants will have hemangiomas that grow very little, whereas others grow rapidly and at an unpredictable rate. Although most are not worrisome, ~12% of IHs are significantly complex, requiring referral to specialists for consideration of treatment.^{1,2} Complications of hemangiomas, for which systemic pharmacotherapy is typically initiated, include permanent disfigurement, ulceration, bleeding, visual compromise, airway obstruction, congestive heart failure and, rarely, death. Despite the relative frequency of IH and the potential severity of complications, uniform guidelines for treatment are lacking.

There are no US Food and Drug Administration (FDA)-approved agents for the treatment of IH, and treatment is currently based on expert opinion and observational studies. Prospective data addressing the efficacy and safety of any pharmacologic interventions for the treatment of IH have not been generated, and available data are confounded by the lack of a consensus on treatment criteria and objective outcome measures. Agents with reported activity in treating IH include corticosteroids, interferon α , vinca alkaloids, and, recently, propranolol.^{3–25}

Since the initial report of propranolol use for the treatment of IH in 2008, there has been a flurry of case reports and case series describing its efficacy and potential side effects.^{3–6,10–15,18,21,23,24,26–36} These publications were not subjected to the usual stringency of phase I/II/III clinical trials, and most were not prospective, randomized, or controlled. With clinical use, propranolol has been found to be rapidly effective for IH, well tolerated, and better than previous therapies at inducing regression. These observations, coupled with the immediate avail-

ability of the medication in a pediatric formulation, have led to a rapid and widespread adoption of propranolol for IH. Propranolol suspension is commercially available in the United States, but it does not currently have an FDA-approved indication for children. Cardiologists have historically used this medication in infants with the diagnosis of supraventricular tachycardia. In contrast to infants with supraventricular tachycardia, for whom initiation of propranolol typically occurs in an inpatient setting with extensive cardiac monitoring, the great majority of infants treated for IH are cardiac healthy and are treated in an outpatient setting. Guidelines for dose initiation, dose escalation, and toxicity monitoring were never generated for use with IH; therefore, each institution designed unique protocols. These protocols vary considerably; some centers hospitalize all children for initiation of treatment, whereas others do so only rarely. Some experts recommend intensive outpatient monitoring of patients, whereas others do little to no monitoring.³

The distinct circumstances in which propranolol has become so widely used underscores the importance of bringing multiple specialties together to gain consensus regarding dose initiation, safety monitoring, dose escalation, and its use in specific situations (eg, PHACE syndrome).³ In this report, we review existing data on the pharmacologic properties of propranolol and all published reports pertaining to the use of propranolol in pediatric patients. With this review as the evidence base,

a multidisciplinary, multiinstitutional expert panel met in December 2011 to develop a standardized, consensus-derived set of best practices for the use of propranolol in infants with IH. As more information accumulates, it is expected that this provisional set of best practices will change.

REVIEW

Pharmacologic Properties of Propranolol

Propranolol is a synthetic, β -adrenergic receptor-blocking agent that is classified as nonselective because it blocks both β -1 and β -2 adrenergic receptors. Chronotropic, inotropic, and vasodilator responses decrease proportionately when propranolol blocks the β -receptor site, resulting in a decrease in heart rate (HR) and blood pressure (BP). Propranolol is highly lipophilic and undergoes first-pass metabolism by the liver with only ~25% of oral propranolol reaching the systemic circulation. Multiple pathways in the cytochrome P450 system are involved in propranolol's metabolism, making clinically important drug interactions a potential issue (Table 1).

Propranolol had previously been used in pediatric patients primarily for the treatment or prevention of cardiac arrhythmias, hypertension, outflow obstructions in congenital heart disease, and hypertrophic cardiomyopathy. Its antihypertensive effects result from decreased HR, decreased cardiac contractility, inhibition of renin release by the kidneys, and decreased sympathetic

TABLE 1 Drug Interactions

Increase Blood Levels/Toxicity	Decrease Blood Levels/Decrease Efficacy
Inhibitors of CYP2D6: Amiodarone, cimetidine (but <u>not</u> ranitidine), delavudin, fluoxetine, paroxetine, quinidine, and ritonavir	Inducers of hepatic drug metabolism: Rifampin, ethanol, phenytoin, and phenobarbital
Inhibitors of CYP1A2: Imipramine, cimetidine, ciprofloxacin, fluvoxamine, isoniazid, ritonavir, theophylline, zileuton, zolmitriptan, and rizatriptan	

tone. However, the mechanism of action of propranolol on IH is yet to be clearly defined. Some of the proposed hypotheses include vasoconstriction, decreased renin production, inhibition of angiogenesis, and stimulation of apoptosis.^{37–39}

Propranolol Use for IH

A comprehensive review of the literature was undertaken to understand the breadth of current clinical practice. A PubMed search cross-referenced with Google Scholar last performed on December 7, 2011, using the search terms “propranolol” and “hemangioma” yielded 177 articles. Of these, 115 articles were written in English and discussed use in humans. Thirty additional articles were excluded because they were nonapplicable or lacked sufficient clinical data. Eighty-five articles (including 1175 patients) were reviewed in detail.^{4,11,13,15,18,21,23,24,26–34,36–38,40–104} The majority of these publications included <5 patients, and nearly all were retrospective reports. There was only 1 prospective trial and 1 meta-analysis.^{58,80} Nearly half (35/85; 41%) of the publications were interim reports with patients still undergoing treatment; therefore, adverse events may be underestimated. Although there was significant variability in the details provided by each article, the authors chose to be inclusive to understand the breadth of current clinical practice.

Response to therapy was discussed in 79 articles, and the definitions and measures of response varied widely, from “stabilization” to “complete response.” Fewer than 10 articles attempted to quantify the degree of involution.^{13,15,23,41,42,58} Positive response in all treated patients was reported in 86% of publications; the remaining 14% discussed at least some treatment failures. In total, 19 of 1175 published patients were reported as treatment failures, suggesting a 1.6% treatment failure rate. This rate may be

underestimated because treatment failures may not be as commonly reported. In publications with adequate data from which to calculate age at initiation of therapy, the mean age was 5.1 months, with a median age of 4 months.

Adverse Events of Propranolol in the Pediatric Population

Although propranolol has been well studied in adults, observations of its use in infants and children, nearly 40 years in duration, have been mainly anecdotal. There are no FDA-approved indications for propranolol in pediatric patients in the United States. There is 1 active phase II/III Investigational New Drug application (ClinicalTrials.gov NCT1056341) for the use of propranolol for the treatment of IH. On the basis of case reports and case series, oral propranolol appears to have a favorable safety profile in children. Deaths or acute heart failure have been associated with propranolol initiation only in the settings of intravenous administration or drug overdose.^{105,106}

Given the variability in study design and the retrospective nature of most reports, the true incidence of adverse

events in IH population is difficult to ascertain. For example, routine screening for bradycardia was only documented in 128 of 1175 (10%) of patients reported. Of the 85 articles, 48 (56%) reported no complications in any patient, although reports of complications with propranolol usage increased over time from 2008 to 2011 (Table 2). The most frequently reported serious complications were asymptomatic hypotension or hypotension for which no additional details were provided; pulmonary symptoms related to direct blockade of adrenergic bronchodilation; hypoglycemia or hypoglycemic seizure; asymptomatic bradycardia; and hyperkalemia. The most commonly reported nonpotentially life-threatening complications were sleep disturbances including nightmares, somnolence, cool or mottled extremities, diarrhea, and gastroesophageal reflux/upset.

Bradycardia and Hypotension

As a β -blocker, propranolol decreases HR and, in part, BP as a result of negative chronotropic and inotropic effects on the heart. Propranolol's effects on BP and HR in children peak

TABLE 2 Complications Due to Propranolol in Hemangioma Patients

Complications Recorded	No. of Patients/ Total No. of Patients in Papers Reporting Complication	Frequency (%) of Complication Among Papers Reporting Said Complication	Overall Frequency (%) of Total of 1175 Patients Reviewed in 85 Papers
Asymptomatic hypotension or hypotension (unspecified)	33/228	14.5	2.8
Symptomatic hypotension	3/46	6.5	0.3
Pulmonary symptoms (bronchoconstriction, bronchiolitis, wheezing, pulmonary obstruction, apneic episode)	16/201	8.0	1.4
Hypoglycemia	10/88	11.4	0.9
Asymptomatic bradycardia or bradycardia (unknown)	11/126	8.7	0.9
Symptomatic bradycardia	1/2	50	0.1
Sleep disturbance (including nightmares)	44/326	13.5	3.7
Somnolence	26/220	11.8	2.2
Cool or mottled extremities	20/225	8.9	1.7
Diarrhea	9/53	17.0	0.8
Gastroesophageal reflux disease or gastrointestinal upset	8/133	6.0	0.7

around 2 hours after an oral dose.⁴⁷ The reported protocols for initial dose, dose titration, and prospective monitoring were extremely variable and therefore difficult to compare in a uniform fashion. Three prospective studies, although limited by small patient numbers and significant missing data, provide useful information. During initiation of propranolol for IH in infants, bradycardia (<2 SD of normal) and hypotension (< 2 SD of normal) after the first dose (2 mg/kg/day divided 3 times daily) were infrequent and asymptomatic.⁴⁷ Changes (*z* scores >2) in systolic BP from baseline occurred in 7%, 22%, and 13% at 1, 2, and 3 hours postpropranolol dosing, respectively. For HR, there were no changes in *z* scores from baseline >2 at any time point measured. As a group, significant changes in BP occurred only at 2 hours.⁴⁷ In 28 patients treated for IH with doses up to 4 mg/kg/day, bradycardia was not noted as a side effect.⁵⁹ In a separate study of 25 infants by Schiestl and colleagues, HR was continuously monitored during sleep and transient bradycardia was reported in 4/25 infants. Decrease in diastolic BP <50th percentile was noted in 16 of 28 patients (57%) in 1 study, but only 1 patient developed clinically recognizable changes with cold extremities and prolonged capillary refill.⁵⁹

Hypoglycemia

Symptomatic hypoglycemia and hypoglycemic seizures have been reported in infants with IH treated with oral propranolol (Table 3).^{59,61,63,64,86,88,90,107} These cases occurred in both newborns and toddlers but were often associated with poor oral intake or concomitant infection. The mechanisms through which propranolol-induced hypoglycemia develops are not completely understood. Non-selective β -blockers, such as propranolol, may block catecholamine-induced glycogenolysis, gluconeogene-

TABLE 3 Hypoglycemia in IH Patients Treated With Propranolol

	Age at Time of Hypoglycemic Episode	Dose	Duration of Propranolol Therapy Before Hypoglycemia	Dose to Detection of Hypoglycemia	Time From Last Dose to Detection of Hypoglycemia	Symptoms	Glucose	Other Factors
Lawley Case 2	36 d	2 mg/kg/day divided TID	10 d	Unknown		Asymptomatic; detected on routine blood work	48 mg/dL	Timing of last meal not specified
Holland Case 1	12 mo	2 mg/kg/day divided TID	3 wk	2 h		Pale, cold, clammy, increasingly unresponsive	55 mg/dL	Fussiness attributed to teething; NI po intake reported
Holland Case 2	18 mo	1.25 mg/kg/day divided BID	Few months	13 h (overnight fast)		Cool, unresponsive after overnight fast; seizures	24 mg/dL	Recent resolution of illness with decreased po intake
Holland Case 3	10 mo	2 mg/kg/day divided TID	8.5 mo	2.5 h		Found limp, pale	20 mg/dL	Setting of RSV, but po intake preceding days reportedly normal
Breur	15 mo	2 mg/kg/day divided BID	3 wk	Several (overnight fast)		Unresponsive in AM	32 mg/dL	Concurrent treatment with prednisone with recent taper; significant HPA axis suppression demonstrated with undetectable AM cortisol
de Graaf Patient 13	32 mo	4 mg/kg; dosing interval NS	NS	NS		Less responsive	48 mg/dL	Prolonged fasting
Bonifazi	6 mo	2 mg/kg/day divided TID	160 d	Propranolol at 3 AM; did not wake at 6 AM		Irritability and seizures upon waking	15 mmol/L	Last meal at 11 PM
Fusilli	6 mo	2 mg/kg/day divided TID	5 mo	Propranolol at 6:30 AM w/o eating, developed seizures at 10 AM (10-h fast)		Seizures	15 mg/dL	
Blatt	8 mo	2.5 mg/kg/day divided BID	2 wk	NS		NS	NS	Dose administered may have been higher because patient had 2 prescriptions (20 mg/5mL and 40 mg/5mL)
Price	NS	NS	NS	NS		NS	NS	Hypoglycemia reported in 1 of 68 patients in study

BID, twice daily; HPA, hypothalamic-pituitary-adrenal; NS, not specified; po, oral administration; RSV, respiratory syncytial virus; TID, 3 times daily.

sis, and lipolysis, predisposing to hypoglycemia. Most of the reported patients who developed hypoglycemia were prescribed relatively low doses (1.25–2.0 mg/kg/day), suggesting that hypoglycemia associated with propranolol may not be dose-dependent. Historically, the 1 reported pediatric fatality from an accidental overdose of oral propranolol had a documented blood glucose level of 0 mg/dL, suggesting that hypoglycemia may be the most serious complication in children.¹⁰⁶ Patients with IH may be at increased risk if they have received or are concomitantly receiving treatment with corticosteroids, because adrenal suppression may result in loss of the counterregulatory cortisol response and increase the risk of hypoglycemia.⁸⁸ Children, infants, and especially preterm infants appear to be at higher risk for this hypoglycemia as their glucose utilization rates are threefold higher in the fasting state and their glycogen stores are lower.¹⁰⁸

Clinical manifestations of hypoglycemia in infants can vary widely. Mild hypoglycemia produces symptoms associated with counterregulatory epinephrine action, including sweating, shakiness, tachycardia, anxiety, and hunger. With propranolol-induced β -adrenergic blockade, early symptoms may be masked. Therefore, because sweating is not typically blocked by β -blockers, this may be a more reliable symptom for diagnosis. More severe hypoglycemia produces symptoms of neuroglycopenia, including lethargy, stupor, poor feeding, seizures, apnea, loss of consciousness, and hypothermia.

Bronchospasm

Bronchial hyperreactivity, described as wheezing, bronchospasm, or exacerbation of asthma/bronchitis, is a recognized side effect of propranolol as the result of its direct blockade of adrenergic bronchodilation. Certainly, the

use of propranolol in the setting of known reactive airway disease must be considered cautiously. The development of bronchial hyperreactivity in the setting of an acute viral illness in patients on propranolol has necessitated temporary discontinuation of therapy.⁵⁹

Hyperkalemia

Hyperkalemia (without electrocardiographic changes) was reported in 2 children on propranolol for IH.^{72,109} The cause of the hyperkalemia is not known, but the authors postulate that it was tumor lysis from the large ulcerated IH combined with impaired potassium uptake into cells as the result of β blockade. Dental caries have been reported in 2 pediatric patients treated with propranolol, although this may be related to the formulation of the suspension (if it contains sucrose). β -adrenergic antagonism of salivary gland function resulting in decreased salivation has also been postulated as a contributing factor.^{58,70}

SURVEY OF PROPRANOLOL USE FOR IH

A survey was designed and was distributed to established prescribers of propranolol in Fall 2011 for IH by Drs Sarah L. Chamlin, Beth A. Drolet, Anita N. Haggstrom, and Anthony J. Mancini.

The response rate was 76%, and most respondents were pediatric dermatologists (88%), academicians (84%), and experienced clinicians with a mean of 15.25 years in practice. Before starting propranolol, the following studies were obtained with the noted frequency: electrocardiogram (ECG; 81%), BP measurement (41%), echocardiogram (38%), and HR measurement (38%). Cardiology consultation was “always obtained” by 34% of respondents and “never obtained” by 25%, with the remainder (41%) stating that they “sometimes obtained” such consultation. Seventeen

(53%) prescribers “always” or “sometimes” admitted patients to the hospital to initiate therapy, with only 3 of these prescribers stating that they always admitted. The other respondents admitting children did so under special circumstances, including young age (under 6–8 weeks), extreme prematurity, significant comorbidity, PHACE syndrome, airway hemangioma, and poor social situations. Most respondents (81%) started propranolol at 0.5 to 1.0 mg/kg per day, with a goal dose of 2.0 mg/kg per day in 84% of patients. Dosing was twice daily for 38% and 3 times daily for 47%, with the remaining 15% dosing 3 times daily initially with a change to twice daily when the child was older (6–12 months of age).

CONSENSUS METHODS

A consensus conference was held in Chicago, Illinois, on December 9, 2011. This conference was sponsored by the National Institute of Arthritis and Musculoskeletal and Skin Diseases (1R34AR060881-01). Twenty-eight participants attended from 12 institutions, representing 5 specialties. Collectively, the group has treated >1000 infants with propranolol for IH. Given the inconsistencies in current institutional policies, consensus was difficult to obtain on all issues. Because of the especially vulnerable patient population of infants aged 1 to 6 months, the group chose to remain cautious in the approach to these recommendations. Where there was considerable controversy, the more conservative approach was selected until additional safety data can be obtained.

Results of the survey were shared, and participants were asked to review all existing literature on the use and adverse effects of propranolol in the treatment of IH, PHACE syndrome, and other indications in the pediatric population. These data were summarized, and work groups were assigned specific

topics to propose protocols on the following subjects: contraindications, special populations, pretreatment evaluation, dose escalation and monitoring, and patient education. These protocols were presented to the entire group and debated using an iterative process (nominal group technique).¹¹⁰ Consensus protocols were recorded during the meeting, refined after the meeting, and resubmitted to the entire group for discussion by teleconference and electronic review. Comments were recorded and discussed, and when appropriate, protocol clarifications and revisions were made and agreed on by the group via teleconference.

Because of the absence of high-quality clinical research data, evidence-based recommendations are not possible at the present time, and these are not American Academy of Pediatrics–endorsed recommendations. However, the multidisciplinary team agreed on a number of recommendations that arose from a review of existing evidence. It is acknowledged that, in many areas, evidence is generally confined to expert opinion, case reports, observational or descriptive studies, and uncontrolled studies. We acknowledge that the following recommendations are conservative in nature, and we anticipate that they will be revised as more data are made available.

CONSENSUS RECOMMENDATIONS

When to Treat IH

Given the wide spectrum of disease and the natural tendency for involution, the greatest challenge in caring for infants with IH is determining which infants are at highest risk for complications and in need of systemic treatment. Medical management is highly individualized, and treatment with oral propranolol is considered in the presence of ulceration, impairment of a vital function (ocular compromise or airway obstruction), or risk of permanent disfigurement. Before

the initiation of therapy, the potential risks of adverse effects are carefully considered and weighed against the benefits of intervention. A medical team with expertise in both the management of IH and the use of oral propranolol in infants provides the most optimal care to patients in need of systemic therapy with propranolol.

Contraindications and Pretreatment History

Before initiating propranolol therapy for IH, screening for risks associated with propranolol use should be performed. Relative contraindications are listed in Table 4. The prescribing physician should perform, or obtain documentation of, a recent normal cardiovascular and pulmonary history and examination. Key elements of the history are poor feeding, dyspnea, tachypnea, diaphoresis, wheezing, heart murmur, or family history of heart block or arrhythmia. The examination should be performed by a care provider with experience in evaluating infants and children. The examination should include HR, BP, and cardiac and pulmonary assessment.

Pretreatment ECG

Routine ECG screening before initiation of propranolol for hemangiomas has been advocated, although the utility of ECG screening for all children with hemangiomas before initiation of propranolol therapy is unclear. In the future, a more indication-driven ECG strategy is likely to develop because the incidence of ECG abnormalities that

would limit propranolol use in children with IH appears low.^{4,7,10,13,15,18,21,25,27,29} For example, congenital complete heart block is rare, with an estimated prevalence of 1 in 20 000 live births,¹¹¹ and this is most commonly associated with maternal connective tissue disease.¹¹² Consensus was not achieved on the use of ECG for all children with IH, but ECG should be part of the pretreatment evaluation in any child when

1. the HR is below normal for age¹¹³:
 - newborns (<1 month old), <70 beats per minute,
 - infants (1–12 months old), <80 beats per minute, and
 - children (>12 months old): <70 beats per minute.
2. there is family history of congenital heart conditions or arrhythmias (eg, heart block, long QT syndrome, sudden death), or maternal history of connective tissue disease.
3. there is history of an arrhythmia or an arrhythmia is auscultated during examination.

Because structural and functional heart disease have not been associated with uncomplicated IH, echocardiography as a routine screening tool before initiation of propranolol is not necessary in the absence of abnormal clinical findings.

Propranolol Use in PHACE Syndrome

PHACE syndrome (Online Mendelian Inheritance in Man database ID 606519) is a cutaneous neurovascular syndrome present in one-third of infants with large, facial hemangiomas; it is characterized by large, segmental hemangiomas of the head and neck and congenital anomalies of the brain, heart, eyes, and/or chest wall.¹¹⁴

Arterial anomalies of the head and neck are the most common noncutaneous manifestation of PHACE syndrome, and acute ischemic stroke is a known

TABLE 4 Contraindications to Propranolol Therapy

Cardiogenic shock
Sinus bradycardia
Hypotension
Greater than first-degree heart block
Heart failure
Bronchial asthma
Hypersensitivity to propranolol hydrochloride

complication.¹¹⁵ Although the arterial anomalies are widely variable, infants with PHACE syndrome believed to be at highest risk for stroke are those with severe, long-segment narrowing or nonvisualization of major cerebral or cervical arteries in the setting of inadequate collateral circulation, especially when there are coexisting cardiac and aortic arch anomalies (Table 5).¹¹⁶ Theoretically, propranolol may increase the risk of stroke in PHACE syndrome patients by dropping BP and attenuating flow through absent, occluded, narrow, or stenotic vessels. Furthermore, nonselective β -blockers, such as propranolol, have been shown to increase variability in systolic BP to a greater degree than β 1-selective agents, and labile BP is a known risk factor for stroke.¹¹⁷ There are 2 reports of acute ischemic stroke in PHACE syndrome patients on propranolol to date. Both patients were concomitantly on oral steroids and had severe arteriopathy.¹¹⁶ Cardiac and aortic arch anomalies are also commonly seen in PHACE syndrome and require echocardiography to assess intracardiac anatomy and function. Propranolol administration in these patients should be managed in close consultation with cardiology.

Infants with PHACE syndrome represent a unique management challenge because most affected infants have extensive facial hemangiomas, with high risk for both medical morbidities and permanent facial scarring. Such patients are thus prime candidates for propranolol therapy.⁴ The potential benefits of treatment must be weighed against the risks. The safe use of propranolol in individuals with PHACE has been described in several small case reports and case series, although no clinical trials have been conducted to assess the overall safety.^{27,115} It is recommended that infants with large facial hemangiomas at risk for

TABLE 5 Imaging and Clinical Features and Stroke Risk in PHACE Syndrome

Risk Category	Cerebrovascular Anomalies
High ^a	<ul style="list-style-type: none">• Multiple vessels with severe narrowing or non-visualization without adequate collateral circulation and Moyamoya disease and Cardiac or Aortic arch anomalies• Severe narrowing/stenosis^b or non-visualization of 1 major vessel^c without adequate collateral circulation and Moyamoya disease and Cardiac or Aortic arch anomalies• Severe narrowing/stenosis^b or non-visualization of 1 major vessel^c without adequate collateral circulation and Moyamoya disease• Severe narrowing/stenosis^b or non-visualization of 1 major vessel^c without adequate collateral circulation and Cardiac or Aortic arch anomalies• Severe narrowing/stenosis^b or non-visualization of 1 major vessel^c without adequate collateral circulation
Standard	<ul style="list-style-type: none">• Severe narrowing/stenosis^b of major vessels^c with adequate collateral circulation• Mild narrowing/stenosis^d of major vessels^c with adequate collateral circulation• Hypoplasia, dysplasia, aberrant origin or course of major vessels^e• Persistent embryonic arteries• Aberrant subclavian artery

^a risk further increased if coexistent cardiac or aortic arch anomalies.
^b defined as vessel narrowing >75%.
^c internal carotid artery, middle cerebral artery, anterior cerebral artery, posterior cerebral artery, basilar artery, vertebral artery.
^d defined as vessel narrowing <75%, and categorized as standard risk given known frequency of overdiagnosis with MRA.
^e any degree of severity.

PHACE be thoroughly evaluated with MRI/magnetic resonance angiography of the head and neck and cardiac imaging to include the aortic arch before considering propranolol. If imaging results place a patient into a higher risk category for stroke (Table 5), consultation and comanagement with neurology is appropriate. If the potential benefits of propranolol outweigh the risks, the consensus group recommends use of the lowest possible dose, slow dosage titration upward, close observation including inpatient hospitalization in high-risk infants, and 3 times daily dosing to minimize abrupt changes in systolic BP.

Formulation, Target Dose, and Frequency

Propranolol is currently commercially available in propranolol hydrochloride oral solution (20 mg/5 mL and 40 mg/5 mL). It is recommended that the 20 mg/5 mL preparation be used because of the small volumes required for this indication. The consensus group recommends a target dose of 1 to 3 mg/kg per day with most members advocating 2 mg/kg per day, the median dose reported in the literature. Given the fact that dose escalation is required with propranolol and that IH often respond rapidly to even low doses, physi-

cians will often use dose response to determine an individual's optimal target dose. Dose escalation from a low starting dose is always recommended even in the presence of inpatient monitoring as the initial cardiac response to β blockade may be pronounced.

The consensus group advocates that the daily dose of propranolol be divided into 3 times daily dosing with a minimum of 6 hours between doses, balancing considerations of safety, efficacy, and convenience.

Initiation of Propranolol in Infants With IH

Some facilities may have the resources and expertise to safely monitor all patients in an outpatient setting, and some practitioners continue to admit all infants. The following suggestions were made regarding monitoring for potential side effects while initiating oral propranolol for the treatment of problematic IH (Fig 1). We acknowledge that the data for safe outpatient initiation is mounting but still relatively limited for this indication. The recommendations are age-dependent with patients divided into 2 age groups.

Inpatient hospitalization for initiation is suggested for the following: Infants \leq 8 weeks of gestationally corrected age, or any age infant with inadequate

social support, or any age infant with comorbid conditions affecting the cardiovascular system, the respiratory system including symptomatic airway hemangiomas or blood glucose maintenance.

Outpatient initiation with monitoring can be considered for infants and toddlers older than 8 weeks of gestationally corrected age with adequate social support and without significant comorbid conditions.

Cardiovascular Monitoring

The peak effect of oral propranolol on HR and BP is 1 to 3 hours after administration. Patients should be monitored with HR and BP measurement at baseline and at 1 and 2 hours after receiving the initial dose, and after significant dose increase (>0.5 mg/kg/day), including at least 1 set of measurements after the target dose has been achieved. If HR and BP are abnormal, the child should be monitored until the vitals normalize. Dose response is usually most dramatic after the first dose; therefore, there is no need to repeat cardiovascular monitoring multiple times for the same dose unless the child is very young or has comorbid conditions affecting the cardiovascular system or the respiratory system including symptomatic airway hemangiomas. Bradycardia is important to recognize because the accurate measurement of BP in infants may be challenging. HR is simple to measure, and normative data for inappropriate bradycardia have been established as follows:

• Newborns (<1 month old), <70 beats per minute

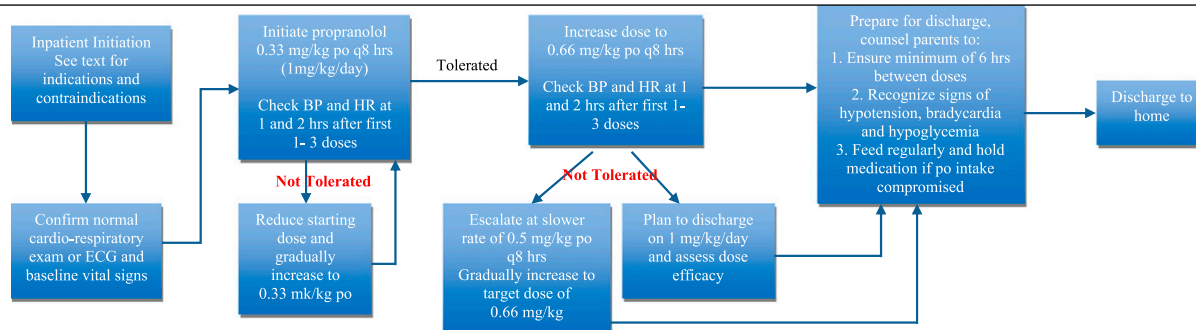
• Infants (1–12 months old), <80 beats per minute

• Children (>12 months old), <70 beats per minute

Systolic BP varies significantly between 1 month and 6 months of age, so normative data are difficult to interpret. Moreover, most pediatric normative BP tables were designed to evaluate for hypertension, not hypotension, and are based on auscultatory measurements.¹¹⁸ Oscillometric devices are convenient and minimize observer error, but they do not provide measures that are identical to auscultation. Obtaining accurate BP measurements in neonates and infants may be challenging, and BP measurements should be obtained by experienced personnel. The infant should be in a warm room and in a resting state, awake or asleep. The use of an appropriately sized infant cuff is essential. The

A

Inpatient Initiation of Propranolol: Suggested for infants <8 weeks of gestationally corrected age or with co-morbid conditions



B

Outpatient Initiation of Propranolol: Suggested for infants >8 weeks of gestationally corrected age and adequate social support.

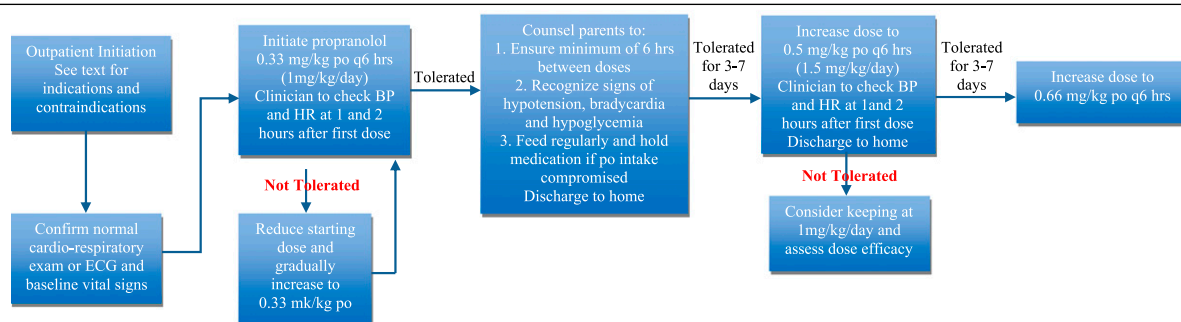


FIGURE 1

(A) Summary of recommended dose initiation for inpatient scenario. (B) Summary of recommended dose initiation for outpatient scenario. PO, oral administration; q6, every 6; q8, every 8.

inflatable portion of the cuff should encircle $\geq 75\%$ of the limb circumference, and the length of the cuff should be at least two-thirds of the length of the upper limb segment. Specific age-based normative parameters for identification of systolic hypotension in infants are difficult to provide; as a general guide, we would describe systolic BP that is below normal (less than fifth percentile oscillometric or < 2 SD of normal auscultation)¹¹⁹ as follows:

- Newborn: < 57 mm Hg (< 5 th percentile oscillometric) or 64 mm Hg (2 SD auscultation)
- 6 months: < 85 mm Hg (< 5 th percentile oscillometric) or 65 mm Hg (2 SD auscultation)
- 1 year: < 88 mm Hg (< 5 th percentile oscillometric) or 66 mm Hg (2 SD auscultation)

Patients who have HR and systolic BP measurements below these values during propranolol initiation/dose escalation warrant careful evaluation for additional evidence of cardiovascular compromise and should be considered at higher risk for continued propranolol use at that dose/continued dosage escalation.

The inpatient and outpatient dose escalation recommendations are age-dependent with patients divided into 2 age groups, as shown in Fig 1.

Ongoing Monitoring

As discussed earlier, patients should be monitored with HR and BP measurement at baseline and at 1 and 2 hours after a significant dose increase (> 0.5 mg/kg/day), including at least 1 set of measurements after the target dose has been achieved. There is no published information on the utility of Holter monitoring in infants after initiating propranolol to identify occult bradycardia or arrhythmias, and this group has not reached consensus on a recommendation for Holter moni-

toring after reaching a steady dose. Most centers represented at the conference do not perform or recommend Holter monitoring in this setting on a routine basis.

Preventing Hypoglycemia

Although recognition of signs or symptoms of hypoglycemia may prompt early intervention, measures should be taken to decrease the risk of hypoglycemia. Because asymptomatic hypoglycemia was not detected in studies that included a random serum glucose as part of routine monitoring, and the timing of hypoglycemic events, as outlined in Table 3, has been variable and unpredictable, routine screening of serum glucose is not indicated. Propranolol should be administered during the daytime hours with a feeding shortly after administration. Parents should be instructed to ensure that their child is fed regularly and to avoid prolonged fasts. In otherwise healthy children, the risk of hypoglycemia is age-dependent and begins after 8 hours of fasting in children 0 to 2 years of age.⁴⁷ Infants < 6 weeks should be fed at least every 4 hours, between 6 weeks and 4 months of age should be fed at least every 5 hours, and > 4 months of age should be fed at least 6 to 8 hours. Propranolol should be discontinued during intercurrent illness, especially in the setting of restricted oral intake. Children undergoing procedures or radiologic imaging requiring fasting for sedation should be supported with Pedialyte (Abbott Nutrition, Abbott Laboratories, Columbus, OH) or glucose-containing IV fluids during perioperative periods. Preoperative blood glucose levels may identify additional patients whose symptoms might otherwise be masked by preoperative medications and anesthesia. Particular care should be taken in using propranolol in preterm infant, patients prescribed other medications known to be associated with

hypoglycemia or with medical conditions known to produce hypoglycemia.

CONCLUSIONS

Currently, the most significant barrier to the implementation of a multiinstitutional clinical trial for the treatment of IH with oral propranolol is the lack of standardized toxicity monitoring in infants without anatomic cardiac/vascular anomalies, as well as in infants with PHACE syndrome. Despite the widespread use of this drug, no

TABLE 6 Consensus Meeting Key Learnings

- There are no FDA-approved indications for propranolol in pediatric patients in the United States.
- There is significant uncertainty and divergence of opinion regarding safety monitoring and dose escalation for propranolol use in IH.
- ECG should be part of the pretreatment evaluation in any child when the HR is below normal, arrhythmia is detected on cardiac exam, or there is a family history of arrhythmias or maternal history of connective tissue disease.
- Cardiac and aortic arch anomalies are commonly seen in PHACE syndrome and require echocardiography to assess intracardiac anatomy and function in at-risk children.
- It is recommended that the 20 mg/5 mL preparation of propranolol be used.
- The consensus group advocates that the daily dose of propranolol be divided into 3 times daily.
- Regardless of the setting in which propranolol is initiated, it is recommended that the propranolol dose be titrated up to a target dose, starting at 1 mg/kg/day divided 3 times daily.
- The peak effect of oral propranolol on HR and BP is 1 to 3 h after administration.
- Dose response is usually most dramatic after the first dose of propranolol.
- Bradycardia may be the most reliable measurement of toxicity because obtaining accurate BPs in infants may be challenging, and normative data for bradycardia are better established.
- If a major escalation in dosage (> 0.5 mg/kg/day) is indicated, the patient's HR should be assessed before, 1 and 2 h after the increased dose is administered.
- Hypoglycemia may be the most common serious complication in children treated with propranolol for IH.
- Propranolol should be discontinued during intercurrent illness, especially in the setting of restricted oral intake to prevent hypoglycemia.

systematic strategy currently exists to identify toxicities of therapy for infants with IH. The consensus team agreed on a number of recommendations that arose from a review of existing evidence

supplemented by expert opinion and clinical experience (Table 6). These recommendations will provide the platform for large-scale phase II/III clinical trials to determine optimal

dosing regimens and long-term safety profiles. We anticipate that these guidelines will be modified as more data are made available from these future studies.

REFERENCES

1. HCUPnet. Healthcare Cost and Utilization Project. Agency for Healthcare Research and Quality. Available at: <http://www.ahrq.gov/data/hcup>. Accessed March 31, 2010
2. Haggstrom AN, Drolet BA, Baselga E, et al. Prospective study of infantile hemangiomas: clinical characteristics predicting complications and treatment. *Pediatrics*. 2006;118(3):882–887
3. Frieden IJ, Drolet BA. Propranolol for infantile hemangiomas: promise, peril, pathogenesis. *Pediatr Dermatol*. 2009;26(5):642–644
4. Léauté-Labrèze C, Dumas de la Roque E, Hubiche T, Boralevi F, Thambo JB, Taïeb A. Propranolol for severe hemangiomas of infancy. *N Engl J Med*. 2008;358(24):2649–2651
5. Léauté-Labrèze C, Sans-Martin V. Hémangiome infantile [Infantile hemangioma]. *Presse Med*. 2010;39(4):499–510
6. Akhavan A, Zippin JH. Current treatments for infantile hemangiomas. *J Drugs Dermatol*. 2010;9(2):176–180
7. Baetz J, Eigelshoven S, Marquard J, Bruch-Gerharz D, Homey B, Meissner T. Infantiles Hämangiome. Erfolgreiche Behandlung mit Propranolol [Infantile hemangioma. Successful treatment with propranolol]. *Hautarzt*. 2010;61(4):290–292
8. Barrio VR, Drolet BA. Treatment of hemangiomas of infancy. *Dermatol Ther*. 2005;18(2):151–159
9. Boon LM, MacDonald DM, Mulliken JB. Complications of systemic corticosteroid therapy for problematic hemangioma. *Plast Reconstr Surg*. 1999;104(6):1616–1623
10. Boyce J, Dodge-Palomba S. Propranolol treatment in periocular pediatric patients with hemangiomas. *Insight*. 2010;35(1):22–23
11. Buckmiller L, Dyamenahalli U, Richter GT. Propranolol for airway hemangiomas: case report of novel treatment. *Laryngoscope*. 2009;119(10):2051–2054
12. Buckmiller LM. Propranolol treatment for infantile hemangiomas. *Curr Opin Otolaryngol Head Neck Surg*. 2009;17(6):458–459
13. Buckmiller LM, Munson PD, Dyamenahalli U, Dai Y, Richter GT. Propranolol for infantile hemangiomas: early experience at a tertiary vascular anomalies center. *Laryngoscope*. 2010;120(4):676–681
14. Denoyelle F, Garabédian EN. Propranolol may become first-line treatment in obstructive subglottic infantile hemangiomas. *Otolaryngol Head Neck Surg*. 2010;142(3):463–464
15. Denoyelle F, Leboulanger N, Enjolras O, Harris R, Roger G, Garabedian EN. Role of Propranolol in the therapeutic strategy of infantile laryngotracheal hemangioma. *Int J Pediatr Otorhinolaryngol*. 2009;73(8):1168–1172
16. Dickie B, Dasgupta R, Nair R, et al. Spectrum of hepatic hemangiomas: management and outcome. *J Pediatr Surg*. 2009;44(1):125–133
17. Draper H, Diamond IR, Temple M, John P, Ng V, Fecteau A. Multimodal management of endangering hepatic hemangioma: impact on transplant avoidance: a descriptive case series. *J Pediatr Surg*. 2008;43(1):120–125, discussion 126
18. Fay A, Nguyen J, Jakobiec FA, Meyer-Junghaenel L, Waner M. Propranolol for isolated orbital infantile hemangioma. *Arch Ophthalmol*. 2010;128(2):256–258
19. Hara K, Yoshida T, Kajiume T, Ohno N, Kawaguchi H, Kobayashi M. Successful treatment of Kasabach-Merritt syndrome with vincristine and diagnosis of the hemangioma using three-dimensional imaging. *Pediatr Hematol Oncol*. 2009;26(5):375–380
20. Herrero Hernández A, Escobosa Sánchez O, Acha García T. Successful treatment with vincristine in PHACES syndrome. *Clin Transl Oncol*. 2007;9(4):262–263
21. Holmes WJ, Mishra A, Gorst C, Liew SH. Propranolol as first-line treatment for infantile hemangiomas. *Plast Reconstr Surg*. 2010;125(1):420–421
22. Hoyoux C. La vincristine: nouveau traitement des hémangiomes infantiles? [Vincristine treatment for management of hemangiomas in infancy]. *Rev Med Liege*. 2008;63(1):14–17
23. Jephson CG, Manunza F, Syed S, Mills NA, Harper J, Hartley BE. Successful treatment of isolated subglottic haemangioma with propranolol alone. *Int J Pediatr Otorhinolaryngol*. 2009;73(12):1821–1823
24. Li YC, McCahon E, Rowe NA, Martin PA, Wilcsek GA, Martin FJ. Successful treatment of infantile haemangiomas of the orbit with propranolol. *Clin Experiment Ophthalmol*. 2010;38(6):554–559
25. Löffler H, Kosel C, Cremer H, Kachel W. Die Propranolol-Therapie in der Behandlung problematischer Hämangiome: Eine neue Standardtherapie kündigt sich an [Propranolol therapy to treat problematic hemangiomas: a new standard therapy makes its debut]. *Hautarzt*. 2009;60(12):1013–1016
26. Fulkerson DH, Agim NG, Al-Shamy G, Metry DW, Izaddoost SA, Jea A. Emergent medical and surgical management of mediastinal infantile hemangioma with symptomatic spinal cord compression: case report and literature review. *Childs Nerv Syst*. 2010;26(12):1799–1805
27. Manunza F, Syed S, Laguda B, et al. Propranolol for complicated infantile haemangiomas: a case series of 30 infants. *Br J Dermatol*. 2010;162(2):466–468
28. Marsciani A, Pericoli R, Alaggio R, Brisigotti M, Vergine G. Massive response of severe infantile hepatic hemangioma to propranolol. *Pediatr Blood Cancer*. 2010;54(1):176
29. Maturo S, Hartnick C. Initial experience using propranolol as the sole treatment for infantile airway hemangiomas. *Int J Pediatr Otorhinolaryngol*. 2010;74(3):323–325
30. Mistry N, Tzifa K. Use of propranolol to treat multicentric airway haemangioma. *J Laryngol Otol*. 2010;124(12):1329–1332
31. Mousa W, Kues K, Haas E, et al. Successful treatment of a large hemangioma with propranolol. *J Dtsch Dermatol Ges*. 2010;8(3):184–186
32. Naouri M, Schill T, Maruani A, Bross F, Lorette G, Rossler J. Successful treatment of ulcerated haemangioma with propranolol. *J*

- Eur Acad Dermatol Venereol.* 2010;24(9): 1109–1112
33. Taban M, Goldberg RA. Propranolol for orbital hemangioma. *Ophthalmology.* 2010;117(1):195.e4
 34. Truong MT, Chang KW, Berk DR, Heerema-McKenney A, Bruckner AL. Propranolol for the treatment of a life-threatening subglottic and mediastinal infantile hemangioma. *J Pediatr.* 2010;156(2):335–338
 35. Storch CH, Hoeger PH. Propranolol for infantile haemangiomas: insights into the molecular mechanisms of action. *Br J Dermatol.* 2010;163(2):269–274
 36. Vanlander A, Decaluwe W, Vandelanotte M, Van Geet C, Cornette L. Propranolol as a novel treatment for congenital visceral haemangioma. *Neonatology.* 2010;98(3): 229–231
 37. Sans V, de la Roque ED, Berge J, et al. Propranolol for severe infantile hemangiomas: follow-up report. *Pediatrics.* 2009; 124(3). Available at: www.pediatrics.org/cgi/content/full/124/3/e423
 38. Schiestl C, Neuhaus K, Zoller S, et al. Efficacy and safety of propranolol as first-line treatment for infantile hemangiomas. *Eur J Pediatr.* 2011;170(4):493–501
 39. Chim H, Armijo BS, Miller E, Gliniak C, Serret MA, Gosain AK. Propranolol induces regression of hemangioma cells through HIF-1 α -mediated inhibition of VEGF-A. *Ann Surg.* 2012;256(1):146–156
 40. Bayliss SJ, Berk DR, Van Hare GF, et al. Re: Propranolol treatment for hemangioma of infancy: risks and recommendations. *Pediatr Dermatol.* 2010;27(3):319–320, author reply 320–321
 41. Haider KM, Plager DA, Neely DE, Eikenberry J, Haggstrom A. Outpatient treatment of periocular infantile hemangiomas with oral propranolol. *J AAPOS.* 2010;14(3):251–256
 42. Cheng JF, Gole GA, Sullivan TJ. Propranolol in the management of periorbital infantile haemangioma. *Clin Experiment Ophthalmol.* 2010;38(6):547–553
 43. Mishra A, Holmes WJ, Gorst C, Liew SH. Role of propranolol in the management of periocular hemangiomas. *Plast Reconstr Surg.* 2010;126(2):671
 44. Erbay A, Sarialioglu F, Malbora B, et al. Propranolol for infantile hemangiomas: a preliminary report on efficacy and safety in very low birth weight infants. *Turk J Pediatr.* 2010;52(5):450–456
 45. Chik KK, Luk CK, Chan HB, Tan HY. Use of propranolol in infantile haemangioma among Chinese children. *Hong Kong Med J.* 2010;16(5):341–346
 46. Le Boulanger N, Fayoux P, Teissier N, et al. Propranolol in the therapeutic strategy of infantile laryngotracheal hemangioma: A preliminary retrospective study of French experience. *Int J Pediatr Otorhinolaryngol.* 2010;74(11):1254–1257
 47. Cushing SL, Boucek RJ, Manning SC, Sidbury R, Perkins JA. Initial experience with a multidisciplinary strategy for initiation of propranolol therapy for infantile hemangiomas. *Otolaryngol Head Neck Surg.* 2011;144(1):78–84
 48. Tan ST, Itinteang T, Leadbitter P. Low-dose propranolol for infantile haemangioma. *J Plast Reconstr Aesthet Surg.* 2011;64(3): 292–299
 49. Zheng JW. Comment on efficacy and safety of propranolol in the treatment of parotid hemangioma. *Cutan Ocul Toxicol.* 2011;30(4):333–334
 50. Zvulunov A, McCuaig C, Frieden IJ, et al. Oral propranolol therapy for infantile hemangiomas beyond the proliferation phase: a multicenter retrospective study. *Pediatr Dermatol.* 2011;28(2):94–98
 51. Bagazgoitia L, Torrelo A, Gutiérrez JC, et al. Propranolol for infantile hemangiomas. *Pediatr Dermatol.* 2011;28(2):108–114
 52. Mishra A, Holmes W, Gorst C, Liew S. Management of complicated facial hemangiomas with beta-blocker (propranolol) therapy. *Plast Reconstr Surg.* 2011;127(4):1742–1743; author reply 3
 53. Kim LH, Hogeling M, Wargon O, Jiwanee A, Adams S. Propranolol: useful therapeutic agent for the treatment of ulcerated infantile hemangiomas. *J Pediatr Surg.* 2011;46(4):759–763
 54. Fuchsmann C, Quintal MC, Giguere C, et al. Propranolol as first-line treatment of head and neck hemangiomas. *Arch Otolaryngol Head Neck Surg.* 2011;137(5): 471–478
 55. Hermans DJ, van Beynum IM, Schultze Kool LJ, van de Kerkhof PC, Wijnen MH, van der Vleuten CJ. Propranolol, a very promising treatment for ulceration in infantile hemangiomas: a study of 20 cases with matched historical controls. *J Am Acad Dermatol.* 2011;64(5):833–838
 56. Saint-Jean M, Léauté-Labrèze C, Mazereeuw-Hautier J, et al; Groupe de Recherche Clinique en Dermatologie Pédiatrique. Propranolol for treatment of ulcerated infantile hemangiomas. *J Am Acad Dermatol.* 2011;64(5):827–832
 57. Al Dhaybi R, Superstein R, Milet A, et al. Treatment of periocular infantile hemangiomas with propranolol: case series of 18 children. *Ophthalmology.* 2011;118(6): 1184–1188
 58. Hogeling M, Adams S, Wargon O. A randomized controlled trial of propranolol for infantile hemangiomas. *Pediatrics.* 2011;128(2). Available at: www.pediatrics.org/cgi/content/full/128/2/e259
 59. de Graaf M, Breur JM, Raphaël MF, Vos M, Breugem CC, Pasmans SG. Adverse effects of propranolol when used in the treatment of hemangiomas: a case series of 28 infants. *J Am Acad Dermatol.* 2011;65(2): 320–327
 60. Truong MT, Perkins JA, Messner AH, Chang KW. Propranolol for the treatment of airway hemangiomas: a case series and treatment algorithm. *Int J Pediatr Otorhinolaryngol.* 2010;74(9):1043–1048
 61. Lawley LP, Siegfried E, Todd JL. Propranolol treatment for hemangioma of infancy: risks and recommendations. *Pediatr Dermatol.* 2009;26(5):610–614
 62. Theletsane T, Redfern A, Raynham O, Harris T, Prose NS, Khumalo NP. Life-threatening infantile haemangioma: a dramatic response to propranolol. *J Eur Acad Dermatol Venereol.* 2009;23(12):1465–1466
 63. Bonifazi E, Acquafredda A, Milano A, Montagna O, Laforgia N. Severe hypoglycemia during successful treatment of diffuse hemangiomatosis with propranolol. *Pediatr Dermatol.* 2010;27(2): 195–196
 64. Holland KE, Frieden IJ, Frommelt PC, Mancini AJ, Wyatt D, Drolet BA. Hypoglycemia in children taking propranolol for the treatment of infantile hemangioma. *Arch Dermatol.* 2010;146(7):775–778
 65. Muthamilselvan S, Vinoth PN, Vilvanathan V, et al. Hepatic haemangioma of infancy: role of propranolol. *Ann Trop Paediatr.* 2010;30(4):335–338
 66. Blanchet C, Nicollas R, Bigorre M, Amedro P, Mondain M. Management of infantile subglottic hemangioma: acebutolol or propranolol? *Int J Pediatr Otorhinolaryngol.* 2010;74(8):959–961
 67. Arneja JS, Pappas PN, Shwayder TA, et al. Management of complicated facial hemangiomas with beta-blocker (propranolol) therapy. *Plast Reconstr Surg.* 2010;126(3):889–895
 68. Abbott J, Parulekar M, Shahidullah H, Taibjee S, Moss C. Diarrhea associated with propranolol treatment for hemangioma of infancy (HOI). *Pediatr Dermatol.* 2010;27(5):558
 69. Jadhav VM, Tolat SN. Dramatic response of propranolol in hemangioma: report of two cases. *Indian J Dermatol Venereol Leprol.* 2010;76(6):691–694

70. Girón-Vallejo O, López-Gutiérrez JC, Fernández-Pineda I, Méndez NA, Ruiz Jiménez JL. Dental caries as a side effect of infantile hemangioma treatment with propranolol solution. *Pediatr Dermatol*. 2010;27(6):672–673
71. Sarialioglu F, Erbay A, Demir S. Response of infantile hepatic hemangioma to propranolol resistant to high-dose methylprednisolone and interferon- α therapy. *Pediatr Blood Cancer*. 2010;55(7):1433–1434
72. Pavlakovic H, Kietz S, Lauerer P, Zutt M, Lakomek M. Hyperkalemia complicating propranolol treatment of an infantile hemangioma. *Pediatrics*. 2010;126(6). Available at: www.pediatrics.org/cgi/content/full/126/6/e1589
73. Fabian ID, Ben-Zion I, Samuel C, Spierer A. Reduction in astigmatism using propranolol as first-line therapy for periocular capillary hemangioma. *Am J Ophthalmol*. 2011;151(1):53–58
74. Missoi TG, Lueder GT, Gilbertson K, Bayliss SJ. Oral propranolol for treatment of periocular infantile hemangiomas. *Arch Ophthalmol*. 2011;129(7):899–903
75. Claerhout I, Buijsrogge M, Delbeke P, et al. The use of propranolol in the treatment of periocular infantile haemangiomas: a review. *Br J Ophthalmol*. 2011;95(9):1199–1202
76. Javia LR, Zur KB, Jacobs IN. Evolving treatments in the management of laryngotracheal hemangiomas: will propranolol supplant steroids and surgery? *Int J Pediatr Otorhinolaryngol*. 2011;75(11):1450–1454
77. Rossler J, Schill T, Bähr A, Truckenmüller W, Noellke P, Niemeyer CM. Propranolol for proliferating infantile haemangioma is superior to corticosteroid therapy—a retrospective, single centre study. *J Eur Acad Dermatol Venereol*. 2012;26(9):1173–1175
78. El-Essawy R, Galal R, Abdelbaki S. Non-selective β -blocker propranolol for orbital and periorbital hemangiomas in infants: a new first-line of treatment? *Clin Ophthalmol*. 2011;5:1639–1644
79. Mazereeuw-Hautier J, Hoeger PH, Benlahrech S, et al. Efficacy of propranolol in hepatic infantile hemangiomas with diffuse neonatal hemangiomatosis. *J Pediatr*. 2010;157(2):340–342
80. Peridis S, Pilgrim G, Athanasopoulos I, Parpounas K. A meta-analysis on the effectiveness of propranolol for the treatment of infantile airway haemangiomas. *Int J Pediatr Otorhinolaryngol*. 2011;75(4):455–460
81. Corapcıoğlu F, Büyükkapu-Bay S, Binnetoğlu K, Babaoglu A, Anik Y, Tugay M. Preliminary results of propranolol treatment for patients with infantile hemangioma. *Turk J Pediatr*. 2011;53(2):137–141
82. Fridman G, Grieser E, Hill R, Khuddus N, Bersani T, Slonim C. Propranolol for the treatment of orbital infantile hemangiomas. *Ophthalm Plast Reconstr Surg*. 2011;27(3):190–194
83. Itani MH, Fakihi H. Response of facial haemangioma to oral propranolol. *BMJ Case Reports*. 2009; doi:10.1136/bcr.01.2009.1476. Available at <http://casereports.bmj.com/content/2009/bcr.01.2009.1476.abstract>. Accessed October 30, 2012
84. Rosbe KW, Suh KY, Meyer AK, Maguiness SM, Frieden IJ. Propranolol in the management of airway infantile hemangiomas. *Arch Otolaryngol Head Neck Surg*. 2010;136(7):658–665
85. Meyer L, Graffstaedt H, Giest H, Truebenbach J, Waner M. Effectiveness of propranolol in a newborn with liver hemangiomatosis. *Eur J Pediatr Surg*. 2010;20(6):414–415
86. Fusilli G, Merico G, Gurrado R, Rosa T, Acquafredda A, Cavallo L. Propranolol for infantile haemangiomas and neuroglycopenic seizures. *Acta Paediatr*. 2010;99(12):1756
87. Mhanna A, Franklin WH, Mancini AJ. Hepatic infantile hemangiomas treated with oral propranolol—a case series. *Pediatr Dermatol*. 2011;28(1):39–45
88. Breur JM, de Graaf M, Breugem CC, Pasmans SG. Hypoglycemia as a result of propranolol during treatment of infantile hemangioma: a case report. *Pediatr Dermatol*. 2011;28(2):169–171
89. Tan ST, Itinteang T, Leadbitter P. Low-dose propranolol for multiple hepatic and cutaneous hemangiomas with deranged liver function. *Pediatrics*. 2011;127(3). Available at: www.pediatrics.org/cgi/content/full/127/3/e772
90. Blatt J, Morrell DS, Buck S, et al. β -blockers for infantile hemangiomas: a single-institution experience. *Clin Pediatr (Phila)*. 2011;50(8):757–763
91. Weiss I, O TM, Lipari BA, Meyer L, Berenstein A, Waner M. Current treatment of parotid hemangiomas. *Laryngoscope*. 2011;121(8):1642–1650
92. Eivazi B, Cremer HJ, Mangold C, Teymoortash A, Wiegand S, Werner JA. Hemangiomas of the nasal tip: an approach to a therapeutic challenge. *Int J Pediatr Otorhinolaryngol*. 2011;75(3):368–375
93. Sierpina DI, Chaudhary HM, Walner DL, Aljadeff G, Dubrow IW. An infantile bronchial hemangioma unresponsive to propranolol therapy: case report and literature review. *Arch Otolaryngol Head Neck Surg*. 2011;137(5):517–521
94. Yeh I, Bruckner AL, Sanchez R, Jeng MR, Newell BD, Frieden IJ. Diffuse infantile hepatic hemangiomas: a report of four cases successfully managed with medical therapy. *Pediatr Dermatol*. 2011;28(3):267–275
95. Koay AC, Choo MM, Nathan AM, Omar A, Lim CT. Combined low-dose oral propranolol and oral prednisolone as first-line treatment in periocular infantile hemangiomas. *J Ocul Pharmacol Ther*. 2011;27(3):309–311
96. Tamagno M, Bibas BJ, Minamoto H, Alfinito FS, Terra RM, Jatene FB. Subglottic and mediastinal hemangioma in a child: treatment with propranolol. *J Bras Pneumol*. 2011;37(3):416–418
97. Guye E, Chollet-Rivier M, Schröder D, Sandu K, Hohlfeld J, de Buys Roessingh A. Propranolol treatment for subglottic haemangioma. *Arch Dis Child Fetal Neonatal Ed*. 2011;96(4):F263–F264
98. Raol N, Metry D, Edmonds J, Chandy B, Sulek M, Larrier D. Propranolol for the treatment of subglottic hemangiomas. *Int J Pediatr Otorhinolaryngol*. 2011;75(12):1510–1514
99. Goswamy J, Rothera MP, Bruce IA. Failure of propranolol in the treatment of childhood haemangiomas of the head and neck. *J Laryngol Otol*. 2011;125(11):1164–1172
100. Moschovi M, Alexiou GA, Stefanaki K, Tourkantonis N, Prodromou N. Propranolol treatment for a giant infantile brain cavernoma. *J Child Neurol*. 2010;25(5):653–655
101. Canadas KT, Baum ED, Lee S, Ostrower ST. Case report: Treatment failure using propranolol for treatment of focal subglottic hemangioma. *Int J Pediatr Otorhinolaryngol*. 2010;74(8):956–958
102. Chun YH, Moon CJ, Yoon JS, Kim HH, Kim JT, Lee JS. Successful treatment of infantile subglottic hemangioma with oral propranolol. *Clin Pediatr (Phila)*. 2012;51(10):983–986
103. Holmes WJ, Mishra A, Gorst C, Liew SH. Propranolol as first-line treatment for rapidly proliferating infantile haemangiomas. *J Plast Reconstr Aesthet Surg*. 2011;64(4):445–451
104. Hermans DJ, van Beynum IM, van der Vijver RJ, Kool LJ, de Blaauw I, van der Vleuten CJ. Kaposiform hemangioendothelioma with

- Kasabach-Merritt syndrome: a new indication for propranolol treatment. *J Pediatr Hematol Oncol*. 2011;33(4):e171–e173
105. Litovitz TL, Schmitz BF, Matyunas N, Martin TG. 1987 annual report of the American Association of Poison Control Centers National Data Collection System. *Am J Emerg Med*. 1988;6(5):479–515
 106. Love JN, Litovitz TL, Howell JM, Clancy C. Characterization of fatal beta blocker ingestion: a review of the American Association of Poison Control Centers data from 1985 to 1995. *J Toxicol Clin Toxicol*. 1997;35(4):353–359
 107. Price CJ, Lattouf C, Baum B, et al. Propranolol vs corticosteroids for infantile hemangiomas: a multicenter retrospective analysis. *Arch Dermatol*. 2011;147(12):1371–1376
 108. van Veen MR, van Hasselt PM, de Sain-van der Velden MG, et al. Metabolic profiles in children during fasting. *Pediatrics*. 2011;127(4). Available at: www.pediatrics.org/cgi/content/full/127/4/e1021
 109. Cavalli R, Buffon RB, de Souza M, Colli AM, Gelmetti C. Tumor lysis syndrome after propranolol therapy in ulcerative infantile hemangioma: rare complication or incidental finding? *Dermatology*. 2012;224(2):106–109
 110. Horton JN. Nominal group technique. A method of decision-making by committee. *Anaesthesia*. 1980;35(8):811–814
 111. Michaëlsson M, Engle MA. Congenital complete heart block: an international study of the natural history. *Cardiovasc Clin*. 1972;4(3):85–101
 112. Vetter VL, Rashkind WJ. Congenital complete heart block and connective-tissue disease. *N Engl J Med*. 1983;309(4):236–238
 113. Bernstein DP, ed. *History and Physical Evaluation*. 18th ed. Philadelphia, PA: Saunders Elsevier; 2007
 114. Frieden IJ, Reese V, Cohen D. PHACE syndrome. The association of posterior fossa brain malformations, hemangiomas, arterial anomalies, coarctation of the aorta and cardiac defects, and eye abnormalities. *Arch Dermatol*. 1996;132(3):307–311
 115. Solomon T, Ninnis J, Deming D, Merritt TA, Hopper A. Use of propranolol for treatment of hemangiomas in PHACE syndrome. *J Perinatol*. 2011;31(11):739–741
 116. Siegel D, Tefft K, Kelly T, et al. Stroke in children with posterior fossa brain malformations, hemangiomas, arterial anomalies, coarctation of the aorta and cardiac defects, and eye abnormalities (PHACE) syndrome: a systematic review of the literature. *Stroke*. 2012;43(6):1672–1674
 117. Webb AJ, Fischer U, Rothwell PM. Effects of β -blocker selectivity on blood pressure variability and stroke: a systematic review. *Neurology*. 2011;77(8):731–737
 118. The fourth report on the diagnosis, evaluation, and treatment of high blood pressure in children and adolescents. *Pediatrics*. 2004;114(suppl 2, 4th report):555–576
 119. Kent AL, Kecskes Z, Shadbolt B, Falk MC. Blood pressure in the first year of life in healthy infants born at term. *Pediatr Nephrol*. 2007;22(10):1743–1749

(Continued from first page)

Given the need for the multispecialty input, this was a highly collaborative process, and all authors have made substantial intellectual contributions to this article. Each author has met all three of the *Pediatrics* criteria. These authors drafted the initial manuscript (specific section in parenthesis) and approved the final manuscript as submitted. Drs Drolet (introduction), Frommelt (pretreatment evaluation), Chamlin (survey), Haggstrom (introduction), and Cassidy conceptualized and designed the consensus conference program and grant award from the National Institutes of Health that supported the consensus conference. These authors also contributed to the acquisition of data by participating in person in the consensus meeting in Chicago and the iterative decision-making process, as well as several conference calls following the meeting. They drafted the initial manuscript and approved the final manuscript as submitted. Drs Frieden (conclusion), Boucek (adverse events), Bauman (proposed dosing regimen), Chiu (methods), Holland (hypoglycemia), Liberman (inpatient dose escalation), Ward (outpatient dose escalation), Metry (PHACE syndrome), and Puttgen (review of the hemangioma literature) contributed to the acquisition of data by participating in person in the consensus meeting and the iterative decision-making process, as well as several conference calls following the meeting. Drs Chun, Garzon, MacLellan-Tobert, Mancini, Seefeldt, Sidbury, Blei, Baselga, Darrow, Joachim, Kwon, Martin, Perkins, and Siegel contributed to the acquisition of data and analysis and interpretation of data by participating in person in the consensus meeting in Chicago and the iterative decision-making process, as well as several conference calls following the meeting. These authors all critically reviewed 11 drafts of this manuscript and approved the final manuscript as submitted.

www.pediatrics.org/cgi/doi/10.1542/peds.2012-1691

doi:10.1542/peds.2012-1691

Accepted for publication Aug 31, 2012

Address correspondence to Beth A. Drolet, MD, Dermatology Department, 8701 Watertown Plank Rd, TBRC, 2nd Floor, Suite C2010, Milwaukee, WI 53226. E-mail: bdrolet@mcw.edu

PEDIATRICS (ISSN Numbers: Print, 0031-4005; Online, 1098-4275).

Copyright © 2013 by the American Academy of Pediatrics

FINANCIAL DISCLOSURE: The following authors disclose a conflict of interest consisting of involvement in the HEMANGIOL study, which was sponsored by Pierre Fabre: Drs Mancini, Sidbury, and Baselga. Drs Frieden and Baselga also disclose that they acted as consultants for Pierre Fabre. The other authors have indicated they have no financial relationships relevant to this article to disclose.

FUNDING: This work was supported by grant NIH-NIAMS-1R34AR060881-01 from the National Institutes of Health/National Institute of Arthritis and Musculoskeletal and Skin Diseases. Funded by the National Institutes of Health (NIH).

Initiation and Use of Propranolol for Infantile Hemangioma: Report of a Consensus Conference

Beth A. Drolet, Peter C. Frommelt, Sarah L. Chamlin, Anita Haggstrom, Nancy M. Bauman, Yvonne E. Chiu, Robert H. Chun, Maria C. Garzon, Kristen E. Holland, Leonardo Liberman, Susan MacLellan-Tobert, Anthony J. Mancini, Denise Metry, Katherine B. Puttgen, Marcia Seefeldt, Robert Sidbury, Kendra M. Ward, Francine Blei, Eulalia Baselga, Laura Cassidy, David H. Darrow, Shawna Joachim, Eun-Kyung M. Kwon, Kari Martin, Jonathan Perkins, Dawn H. Siegel, Robert J. Boucek and Ilona J. Frieden

Pediatrics 2013;131;128; originally published online December 24, 2012;

DOI: 10.1542/peds.2012-1691

Updated Information & Services	including high resolution figures, can be found at: http://pediatrics.aappublications.org/content/131/1/128.full.html
References	This article cites 111 articles, 13 of which can be accessed free at: http://pediatrics.aappublications.org/content/131/1/128.full.html#ref-list-1
Citations	This article has been cited by 2 HighWire-hosted articles: http://pediatrics.aappublications.org/content/131/1/128.full.html#related-urls
Post-Publication Peer Reviews (P³Rs)	3 P ³ Rs have been posted to this article http://pediatrics.aappublications.org/cgi/eletters/131/1/128
Subspecialty Collections	This article, along with others on similar topics, appears in the following collection(s): Allergy & Dermatology http://pediatrics.aappublications.org/cgi/collection/allergy_and_dermatology
Permissions & Licensing	Information about reproducing this article in parts (figures, tables) or in its entirety can be found online at: http://pediatrics.aappublications.org/site/misc/Permissions.xhtml
Reprints	Information about ordering reprints can be found online: http://pediatrics.aappublications.org/site/misc/reprints.xhtml

PEDIATRICS is the official journal of the American Academy of Pediatrics. A monthly publication, it has been published continuously since 1948. PEDIATRICS is owned, published, and trademarked by the American Academy of Pediatrics, 141 Northwest Point Boulevard, Elk Grove Village, Illinois, 60007. Copyright © 2013 by the American Academy of Pediatrics. All rights reserved. Print ISSN: 0031-4005. Online ISSN: 1098-4275.

American Academy of Pediatrics

DEDICATED TO THE HEALTH OF ALL CHILDREN™

